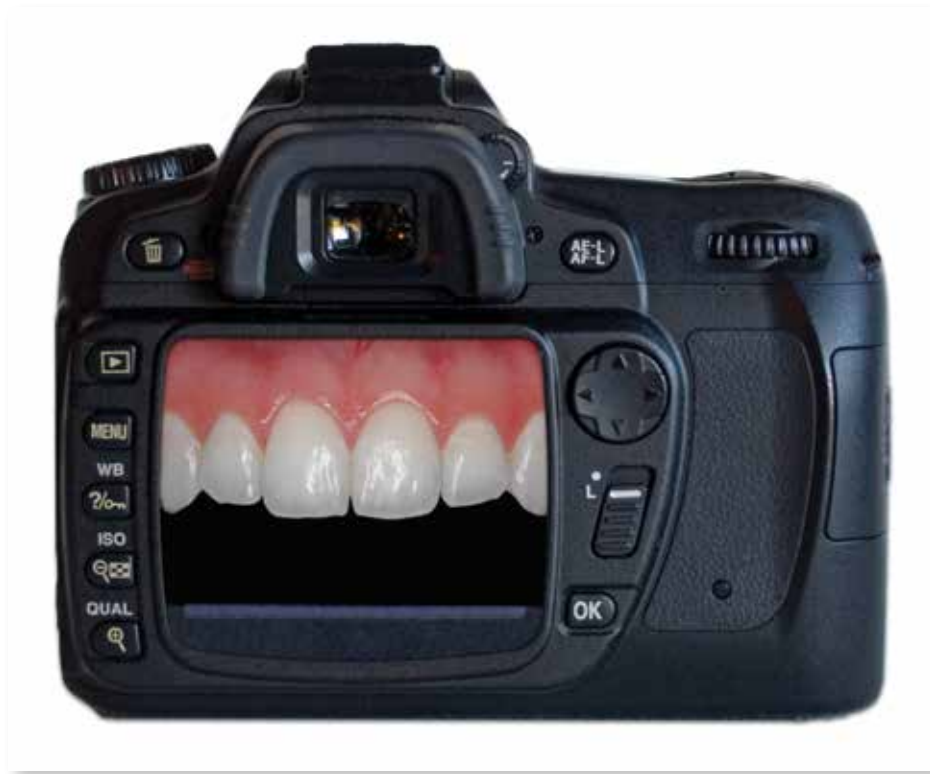

# PHOTOGRAPHIC DOCUMENTATION AND EVALUATION IN COSMETIC DENTISTRY



## A GUIDE TO ACCREDITATION PHOTOGRAPHY

**AACD** American Academy  
of Cosmetic Dentistry®

# A GUIDE TO ACCREDITATION PHOTOGRAPHY

Copyright© 2009-2013 American Academy of Cosmetic Dentistry



*This dental photography guide has been produced by the American Academy of Cosmetic Dentistry® under the supervision of the American Board of Cosmetic Dentistry®. All materials contained herein are the sole property of the AACD and may not be reproduced without the written permission of the American Academy of Cosmetic Dentistry®.*

## INTRODUCTION

In 1984 the American Academy of Cosmetic Dentistry (AACD) was formed by a group of forward thinking individuals dedicated to continuing education in the rapidly evolving fields of dental materials and cosmetic dentistry. Within a short period of time, the AACD developed a credentialing process in cosmetic dentistry designated "Accreditation". As techniques and materials have developed, the Accreditation examination has continued to set a standard for clinical excellence. Successfully achieving Accredited status from the AACD requires dedication to continuing education, strict adherence to the protocol, and a resolve to produce exceptional dentistry. The process of Accreditation is comprised of three successive tiers:

- Written Examination
- Clinical Case Examinations
- Oral Examination

Detailed information regarding the testing protocols for dentists and laboratory technicians may be obtained from the AACD Executive Office 608.222.8583 or the AACD Web site [www.aacd.com](http://www.aacd.com). This guide is designed to define the photographic requirements for the clinical case examination aspect of the Accreditation examination.

### ACCREDITATION DIGITAL PHOTOGRAPHIC DOCUMENTATION

The images in this manual represent the specific documentation required for the clinical case submission portion of the AACD Accreditation examination. Proper documentation is necessary for self-critique and the examination process. It is advisable to use this guide as a companion to courses specifically geared toward dental photography. The AACD will not define specific equipment requirements; however, the AACD has outlined criteria to produce high quality images. The protocol and equipment recommendations are expected to evolve with advances in technology. Digital image quality is contingent upon correct color and exposure, depth of field, good tonal range, and image sharpness. Proper setup and use of your camera and adjunctive photographic equipment enhances quality results. A professional grade single lens reflex digital camera, with a macro lens capable of manual focus and selectable magnification ratio with a lens mounted flash, is recommended.

Digital dental cameras have evolved over the last 10 years. Be certain to purchase compatible components, new or used, as opposed to equipment that has been pieced together. 'Point and Shoot' cameras with diffusers are not recommended for Accreditation photographic documentation. The small capture chips and internal firmware in these types of cameras capture images that are visibly degraded. In addition, image quality is lessened by an inability to control exposure and depth of field during macro image capture. The digital camera should be at least five megapixels and capable of capturing images in a RAW format. Different camera manufacturers use different names for RAW files. Images for Accreditation should be captured and saved in the camera's proprietary RAW format. For more details, review the Accreditation photographic protocols listed at [www.aacd.com](http://www.aacd.com).

### EDUCATIONAL FORMAT OF THIS MANUAL

This guide focuses on consistency of photographic views required for AACD Accreditation, but can also be a valuable tool for establishing standardized documentation of dentistry outside the AACD credentialing process. Additional images may be a necessary adjunct in establishing a diagnosis, developing a treatment plan, and documenting treatment. Cases submitted for Accreditation review, for dentists and laboratory technicians, should include the required clinical views represented in this manual. Examples of the required technique views for dentists and laboratory technicians are also included in this manual (technique view requirements vary for dentists and laboratory technicians). More detailed descriptions of the technique views are described for dentists and laboratory technicians in the Accreditation protocols, listed on the Academy's Web site [www.aacd.com](http://www.aacd.com).

## REQUIRED VIEWS FOR CLINICAL CASE SUBMISSIONS

There are 24 views required for all clinical case examinations. Of the 24 views, 12 should be taken before treatment and 12 after treatment. Additional views are required for the technique documentation (see [www.aacd.com](http://www.aacd.com) for additional information). Images may be captured in either manual or TTL mode. All intraoral images should be captured using high f-stops to maximize depth of field.

### MAGNIFICATION

Images of the required views will be captured at one of three magnification ratios (1:10, 1:2, 1:1). Make any necessary magnification conversions to produce an image magnification comparable to the images illustrated in the photography guide. Lens magnification conversion is needed for many digital SLR cameras without full frame sensors. Settings will vary with sensor and face size. Cameras with smaller sensors will require approximately a 1.5 times increase in the setting on the lens barrel [1:10 (1:15), 1:2 (1:3), 1:1 (1:1.5)].

### VIEWS

#### NON-RETRACTED VIEWS

1. Natural Full Face – frontal view – 1:10 (1:15) magnification
2. Full Natural Smile – frontal view – 1:2 (1:3) magnification
3. Full Natural Smile – right lateral view – 1:2 (1:3) magnification
4. Full Natural Smile – left lateral view – 1:2 (1:3) magnification

#### RETRACTED VIEWS

5. Upper and lower teeth slightly parted – frontal view – 1:2 (1:3) magnification
6. Upper and lower teeth slightly parted – right lateral view – 1:2 (1:3) magnification
7. Upper and lower teeth slightly parted – left lateral view – 1:2 (1:3) magnification
8. Maxillary anterior in view only – frontal view – 1:1 (1:1.5) magnification
9. Maxillary anterior in view only – right lateral view – 1:1 (1:1.5) magnification
10. Maxillary anterior in view only – left lateral view – 1:1 (1:1.5) magnification

#### RETRACTED VIEWS USING A MIRROR

11. Maxillary arch – occlusal view – 1:2 (1:3) magnification
12. Mandibular arch – occlusal view – 1:2 (1:3) magnification

## ISSUES THAT APPLY TO ALL IMAGES

*Note: All images should be properly exposed. The intraoral images should be free of saliva, distractions, and debris. Any factors that compromise proper evaluation of clinical cases will be viewed negatively and may prevent examiners from considering the case for the examination process. Please refer to the common errors section for examples.*

### ELIMINATE DEBRIS AND DISTRACTIONS

- Saliva, surface sealants, and other forms of excess moisture
- Plaque, calculus, blood, and food debris
- Makeup, glove powder, and/or lipstick on teeth
- Excess cement beyond margins of restorations

### USE THE PROPER CAMERA ANGLE AND POSITION RELATIVE TO THE SUBJECT

- The camera should be positioned 90 degrees horizontally and vertically to the subject.
- Framing an image from above or below the subject can alter the perception of the plane of the teeth.

### USE A UNIFORM, NON-DISTRACTING BACKGROUND

- The before and after photograph background should be consistent
- The use of a non-distracting, neutral background (light grey) is recommended
- Certain views do not require a background – see photo examples
- A contrasting device is optional for retracted 1:1 (1:1.5) views. If one is employed, it should be utilized consistently throughout documentation of the case

### POSITION THE CAMERA PROPERLY TO AVOID TILTING (CANTING) OF THE PHOTOGRAPH

- Facial asymmetries should be reproduced in the photograph. Do not tilt the camera to compensate for canted teeth or soft tissues
- It may be necessary to reposition the patient to avoid leaning while exposing the image. This may require moving the patient from the dental chair to another chair or to a standing position

### USE PROPER FRAMING, EXPOSURE, AND FOCUS

## FULL FACE

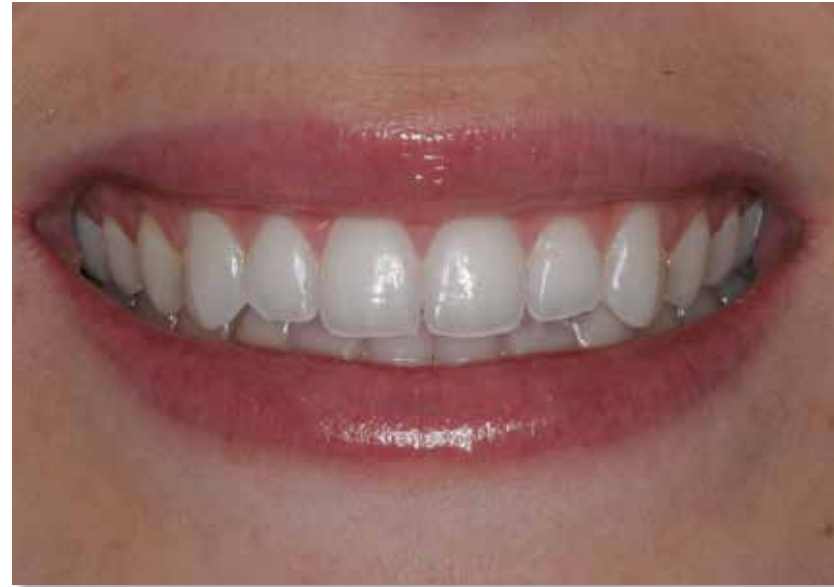FRONTAL VIEW  
1:10 (1:15) MAGNIFICATION  
NON-RETRACTED VIEW



- *Horizontal Orientation Only* – do not turn camera for vertical orientation. The image should be framed with the chin near the lower border. The head, for most patients, should be in full view. With a 1:10 (1:15) magnification, the patient's neck will probably be out of frame.
- The patient should exhibit a full *natural smile* with facial muscles relaxed.
- The patient's nose should be in the center of the image.
- Use the interpupillary line and vertical midline of the face to orient the camera. Do not use the lips or teeth to determine alignment as they are less reliable references for orientation.
- Position the patient so that no shadowing is apparent on the background. Shadows usually indicate the subject is too close to the background.
- Use a uniform, non-distracting background.
- Image should be taken directly in front of the patient. Avoid angulation problems that will affect the appearance of the incisal plane.

## FULL SMILE

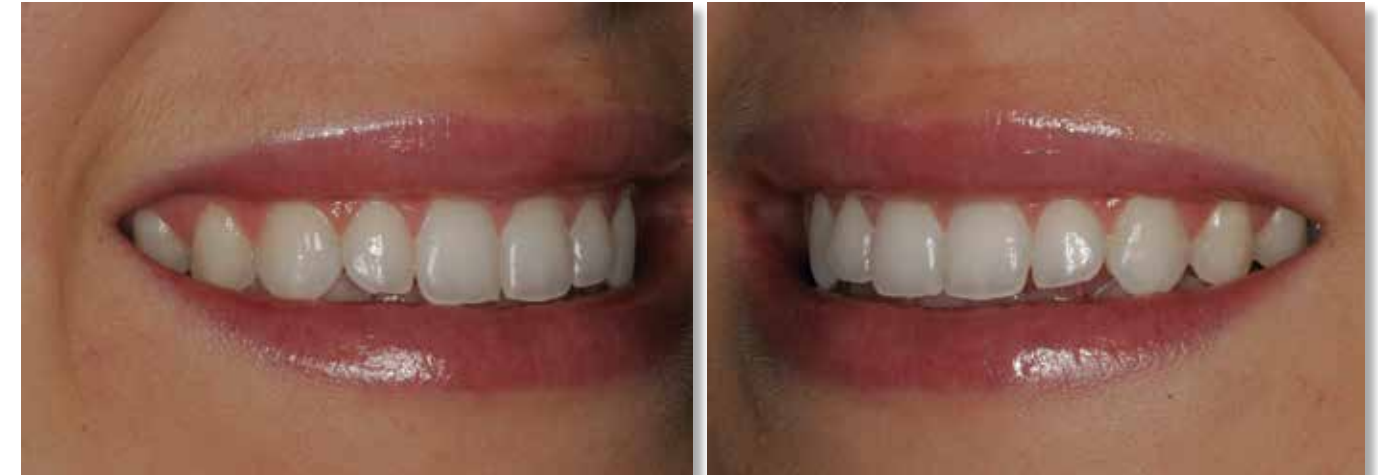FRONTAL VIEW  
1:2 (1:3) MAGNIFICATION  
NON-RETRACTED VIEW



- Show a *full* natural smile. Document the maximum amount of teeth and gingiva the patient normally displays when laughing or broadly smiling. Facial muscles should appear relaxed.
- The vertical center of the slide should be the philtrum of the upper lip.
- Do not compensate for a midline discrepancy.
- The incisal plane of the upper teeth should be the horizontal midline of the image. If the patient has a canted incisal plane as evident in the full face view, it should be duplicated in this view. Do not tilt the camera to compensate for canted teeth.
- The image should be taken directly in front of the patient.
- Avoid angulation problems that will affect the appearance of the incisal plane. The camera should be 90 degrees to the subject both horizontally and vertically to prevent the illusion of a canted or inverse incisal plane.
- Using a 1:2 (1:3) magnification, the patient's lips should be completely in the frame. All teeth normally viewed in a full natural smile should be in the image. Note that mandibular teeth may not be visible.
- Focus on the centrals and laterals. Proper depth of field (achieved with a high f-stop) will allow for the other visible teeth to be in focus.
- No background is necessary for this view.

## FULL SMILE

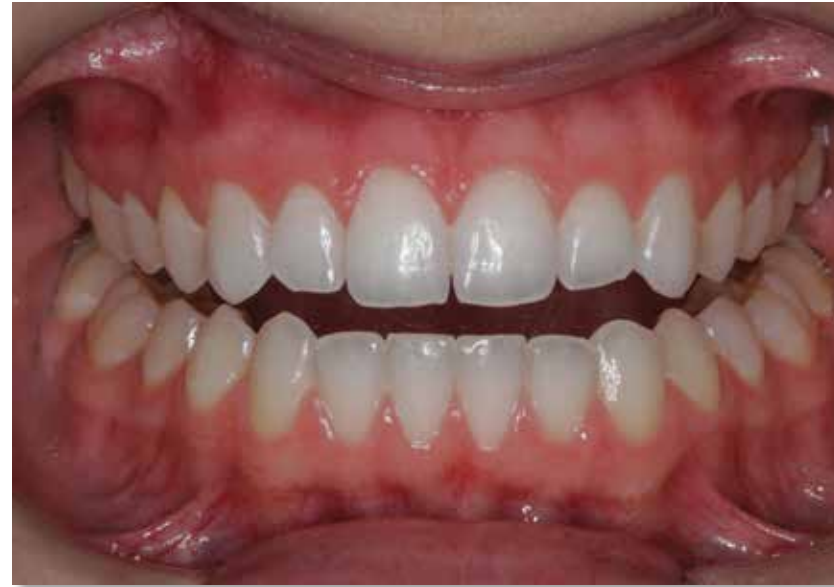RIGHT AND LEFT LATERAL VIEWS  
1:2 (1:3) MAGNIFICATION  
NON-RETRACTED VIEW



- Show a *full* natural smile. Document the maximum amount of teeth and gingiva the patient normally displays. Facial muscles should appear relaxed.
- The vertical midline of the image should be the lateral incisor.
- The horizontal midline of the image should be the incisal plane, perpendicular to the vertical midline.
- Focus on the lateral incisor. Proper depth of field should allow for the other visible teeth to be in focus.
- This is not a profile (sagittal) view. The contralateral central incisor, and possibly the contralateral lateral incisor and canine should be visible, based on arch size.
- Some background may be visible. If necessary, place the background on the contralateral side of the patient in a position that will not result in shadowing. It is possible that under certain conditions, the area behind the patient may appear black even without a background, based on flash position and depth of field. Reproduce natural asymmetry.
- Maintain 1:2 (1:3) magnification.

## UPPER AND LOWER TEETH

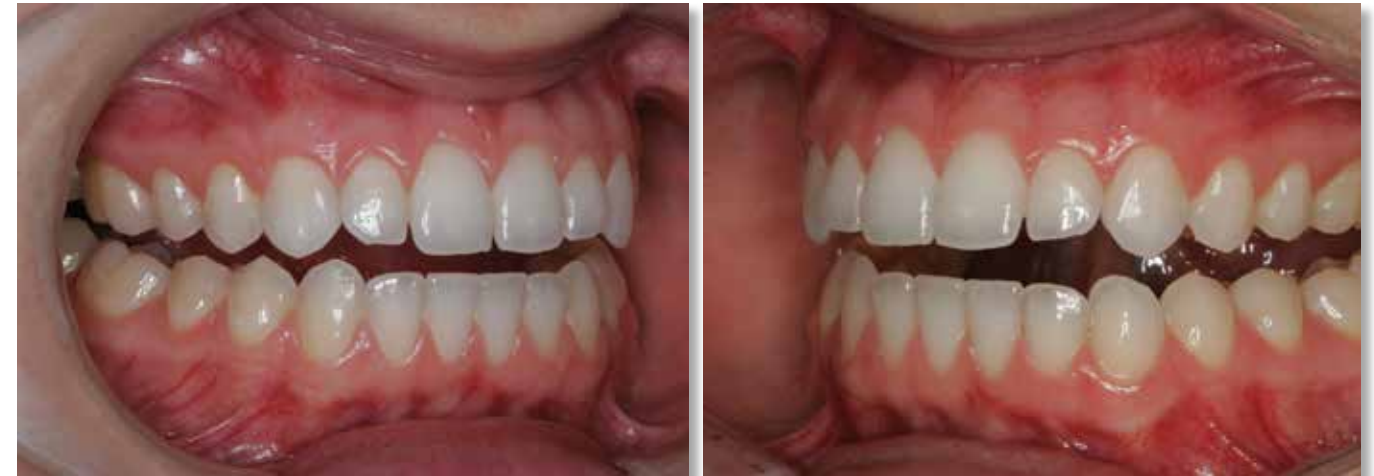FRONTAL VIEW  
1:2 (1:3) MAGNIFICATION  
RETRACTED VIEW



- The upper and lower teeth should be slightly parted so the incisal edges are visible. This allows for evaluation of incisal plane and incisal embrasures.
- Show as much gingiva as possible. Position the retractors symmetrically to avoid the appearance of a canted image. Pull the retractors out and away from the teeth before exposing the image.
- Minimize the appearance of lips and retractors in the image.
- Treated teeth and adjacent tissue must be completely and clearly visible. Gingival height and contour cannot be obscured.
- The midline of the face should be used as the vertical midline of the image. The philtrum of the lip may be helpful, although retractors can cause some soft tissue distortion. Reproduce any asymmetry or canting of the teeth consistent with the full face view.
- The horizontal midline of the image should be the incisal plane of the upper teeth, perpendicular to the vertical midline.
- Position the camera directly in front and 90 degrees to the subject. Avoid tilting the camera and vertical camera angle problems (taking the image from above or below the subject).
- Focus on central and lateral incisors. Proper depth of field (high f-stop) will allow other visible teeth to be in focus.
- Tongue should be positioned away from the teeth to avoid distraction.
- A 1:2 (1:3) magnification should show both arches completely and in focus.

## UPPER AND LOWER TEETH

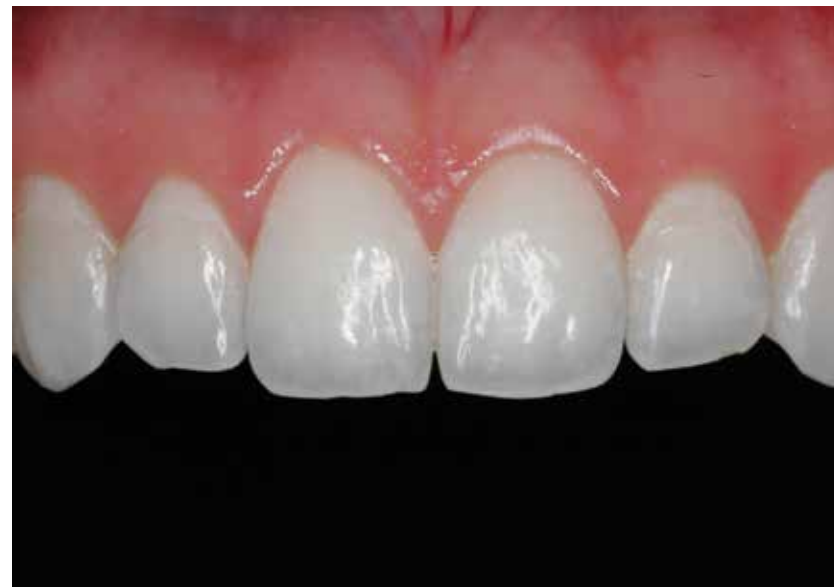RIGHT AND LEFT LATERAL VIEW  
1:2 (1:3) MAGNIFICATION  
RETRACTED VIEW



- The upper and lower teeth should be slightly parted so the incisal edges are visible. This allows for evaluation of incisal plane and incisal embrasures.
- Show as much gingiva as possible. Rotate the retractors toward the image side, while pulling the retractors out and away from the teeth.
- Minimize the appearance of lips and retractors in the image.
- Treated teeth and adjacent tissue must be completely and clearly visible. Gingival height and contour cannot be obscured.
- The vertical midline of the image should be the lateral incisor.
- The horizontal midline of the image should be the incisal plane, perpendicular to the vertical midline. Reproduce natural asymmetry.
- Focus on the lateral incisor. Proper depth of field (high f-stop) will allow other visible teeth to be in focus. Tongue should be positioned away from the teeth to avoid distraction. Maintain 1:2 (1:3) magnification.
- This is not a profile (sagittal) view. The contralateral central incisor and possibly the contralateral lateral incisor and canine should be visible, based on arch size. Remember to center the image on the lateral incisor.
- If retracted and framed properly, the contralateral cheek will obscure most of the background area.

## MAXILLARY ANTERIOR VIEW

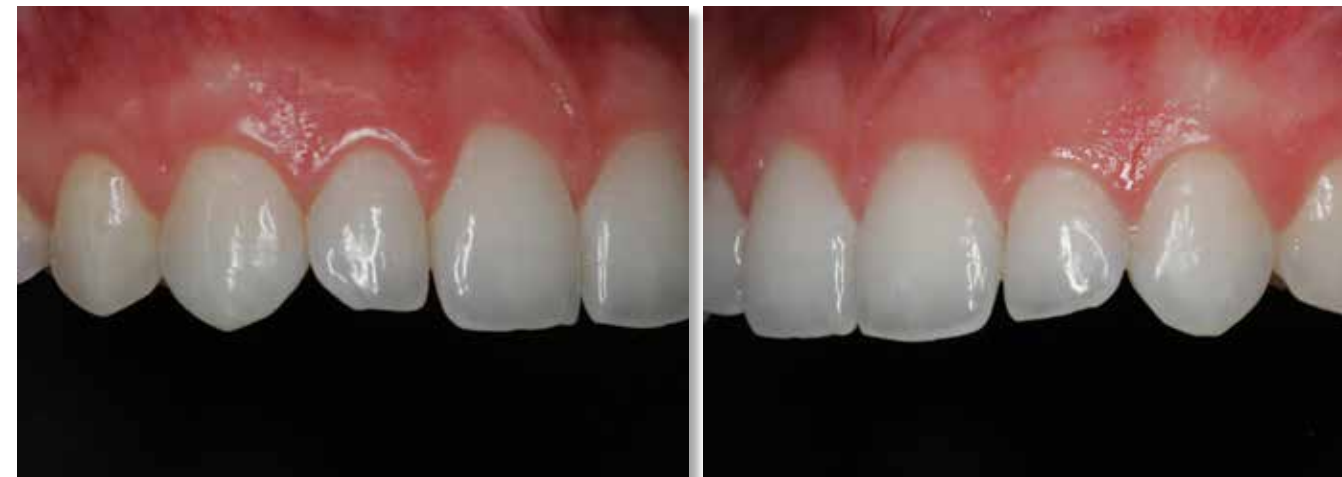FRONTAL VIEW  
1:1 (1:1.5) MAGNIFICATION  
RETRACTED VIEW



- The maxillary anterior teeth should be centered in the view, using the midline and frenum as references, to bisect the image vertically. The philtrum of the lip will not be visible.
- Horizontally the midline of the image should bisect the central incisors (do not use the incisal plane as the horizontal midline).
- No retractors should be visible. The gingiva adjacent to the teeth in the frame should be clearly visible.
- The opposing teeth should not be visible.
- A contrasting device is optional. If used, place it so as not to create a shadow.
- Take the image at 90 degrees to the subject and directly in front of the patient.
- In a 1:1 (1:1.5) view, only 4 to 6 upper teeth should be in the frame.

## MAXILLARY ANTERIOR VIEW

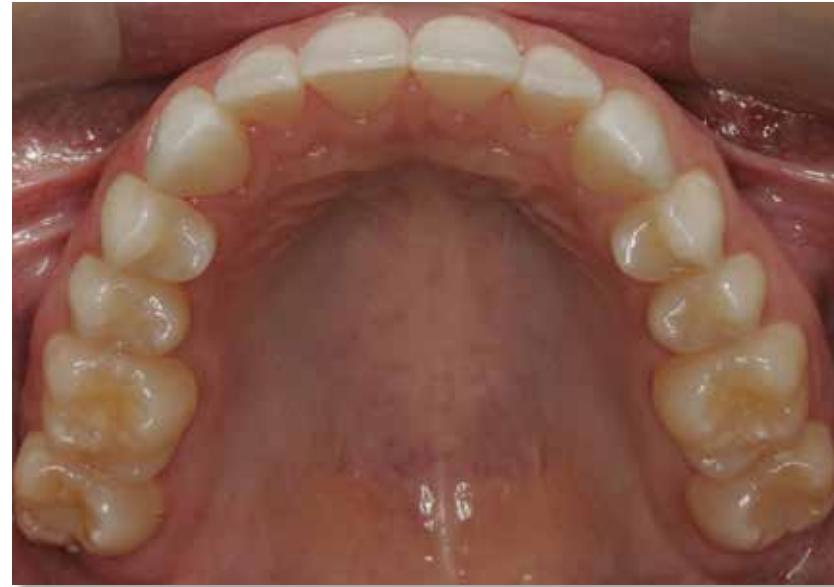RIGHT AND LEFT LATERAL VIEW  
1:1 (1:1.5) MAGNIFICATION  
RETRACTED VIEW



- In the view, the lateral incisor should be centered to bisect the image vertically.
- Horizontally the midline of the image should bisect the lateral incisor (do not use the incisal plane as the horizontal midline).
- No retractors should be visible. The gingiva adjacent to the teeth in the frame should be clearly visible.
- The opposing teeth should not be visible.
- A contrasting device is optional. If used, place it so as not to create a shadow.
- Take the image at 90 degrees to the facial of the lateral incisor.
- Rotate the image side retractor toward the posterior and the contralateral retractor slightly forward. Both retractors should be pulled out and away from the teeth.
- In a 1:1 (1:1.5) view, only 4 to 6 upper teeth should be in the frame.

## MAXILLARY ARCH

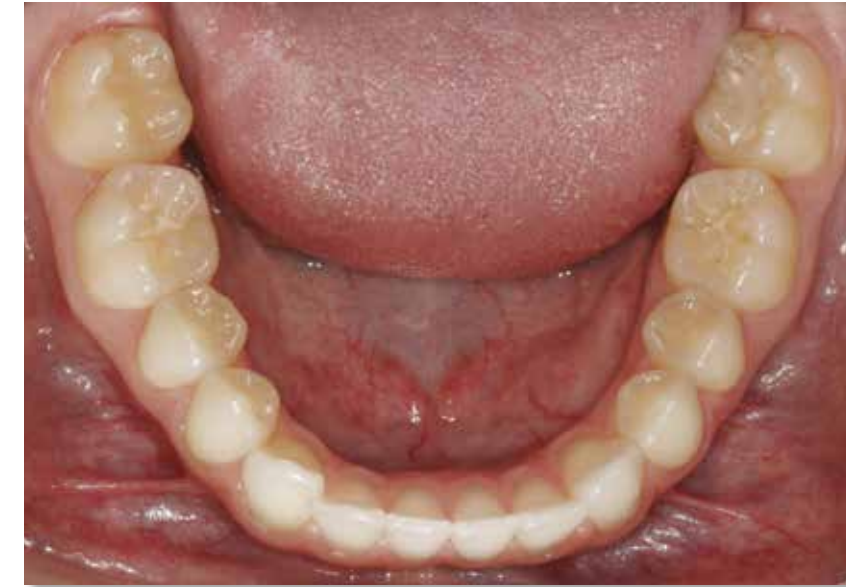OCCLUSAL VIEW  
1:2 (1:3) MAGNIFICATION  
RETRACTED WITH MIRROR VIEW



- The occlusal view is *always* taken using a high quality mirror, resulting in an image of the reflected image.
- Do *not* attempt to take this image without retractors. The soft tissue will collapse around the mirror and obstruct the view.
- The facial surfaces of the central incisors should be visible near the edge of the image.
- Frame the image so mirror edges and lips are minimized. The patient's nose and unreflected teeth should not be visible.
- Eliminate fog on the mirror. A gentle stream of air will help or warm the mirror in a water bath.
- Take the image at approximately 45 degrees to the mirror surface. The mirror placement should allow for the facial and lingual surfaces to be seen equally. A shallow photographic angle to the mirror will prevent proper documentation of facial and lingual embrasure form.
- Show as many teeth as possible. The image should extend from the central incisors to the mesial of the second molars at minimum. The anterior teeth should always be clearly shown.
- The image should clearly show the incisal edge position of the maxillary anterior teeth and facial and lingual embrasures.
- This image can be taken from either in front of the patient (partially reclined) or directly behind the patient with the patient fully reclined.
- Focus on the reflected image of the bicuspid.
- Start with a 1:2 (1:3) magnification and adjust the magnification as needed to frame the maxillary arch.

## MANDIBULAR ARCH

OCCLUSAL VIEW  
1:2 (1:3) MAGNIFICATION  
RETRACTED WITH MIRROR VIEW



- The occlusal view is always taken using a high quality mirror, resulting in an image of the reflected image. Do not attempt to take this image without retractors – the soft tissue may obstruct the view.
- The facial surfaces of the central incisors should be visible near the edge of the image.
- Frame the image so mirror edges and lips are minimized. The patient's nose and unreflected teeth should not be visible.
- Eliminate fog on the mirror. A gentle stream of air will help or warm the mirror in a water bath.
- Take the image at approximately 45 degrees to the mirror surface. The mirror placement should allow for the facial and lingual surfaces to be seen equally. A shallow photographic angle to the mirror will prevent proper documentation of facial and lingual embrasure form.
- Show as many teeth as possible. The image should extend from the central incisors to the mesial of the second molars at minimum. The anterior teeth should always be clearly shown.
- The image should clearly show the incisal edge position of the mandibular anterior teeth and facial and lingual embrasures.
- This image can be taken from in front of the patient (partially reclined with head tilted back). Taking this image from behind the patient is difficult and requires an inverted body position with the head tilted back.
- The patient's tongue should not obscure the teeth. It will be helpful if the patient's tongue can be moved to the posterior. It may also be possible to retract the tongue with the mirror.
- Focus on the reflected image of the bicuspid.
- Start with a 1:2 (1:3) magnification and adjust the magnification as needed to frame the mandibular arch.



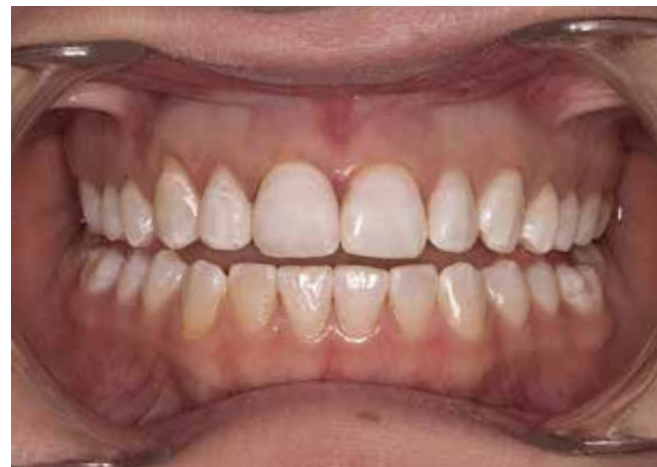## ADDITIONAL PHOTOGRAPHIC DOCUMENTATION FOR DENTISTS – CASE TYPE V

### OCCLUSAL VIEW 1:2 (1:3) MAGNIFICATION RETRACTED WITH MIRROR VIEW

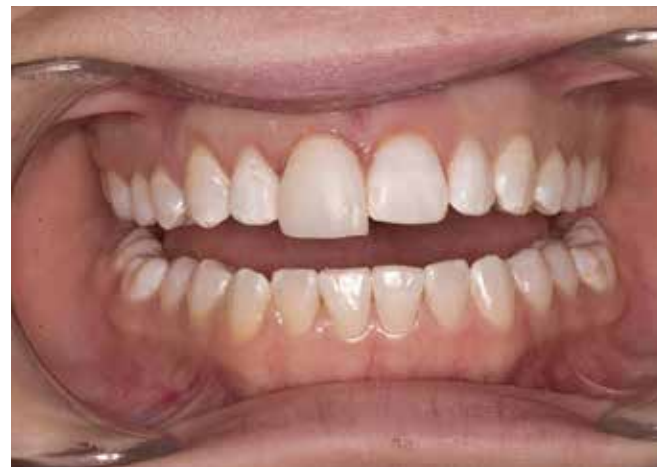The following is an example of the additional images required to document Case Type V - Six or More Direct Resin Veneers. These photos are to be taken at 1:2 (1:3) magnification or digital equivalent. If teeth are treated sequentially rather than simultaneously, use a central incisor to illustrate views 1 – 4. Technique image 5 should be taken prior to final polishing and should show all restored teeth.

Techniques 1 - 5:

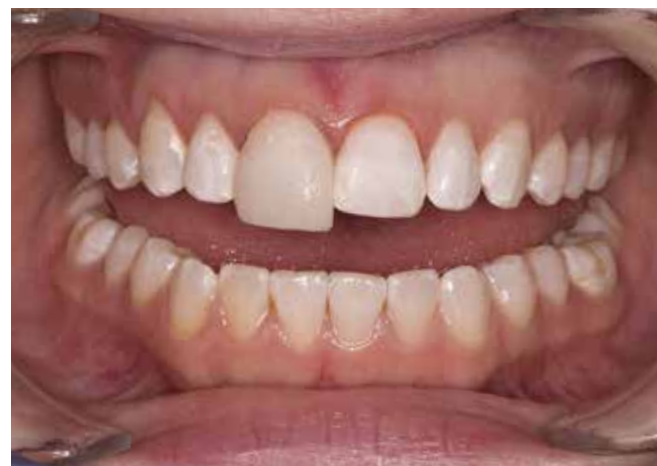1. Initial preparation, beveling and/or abrasion of tooth surfaces
2. Initial layer of restorative resin (after curing, before contouring)
3. Application of tints and opaquers (if used) **Image Not Shown**
4. Final layer of resin (bulk layer, after curing, before contouring or finishing)
5. After contouring, but before polishing



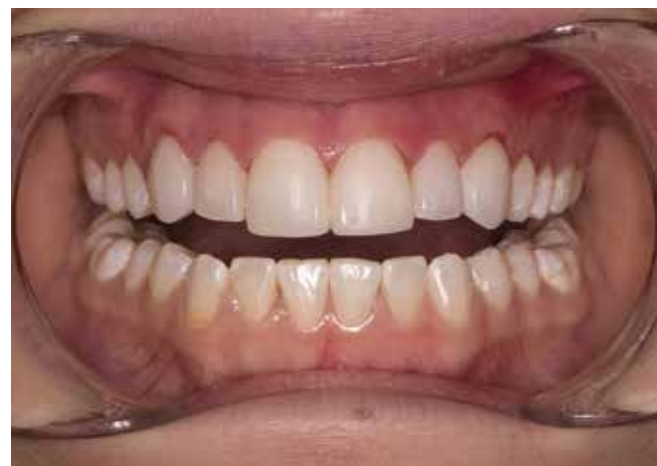1. Initial preparation, beveling and/or abrasion of tooth surfaces



2. Initial layer of restorative resin (after curing, before contouring)



4. Final layer of resin (bulk layer, after curing, before contouring or finishing)

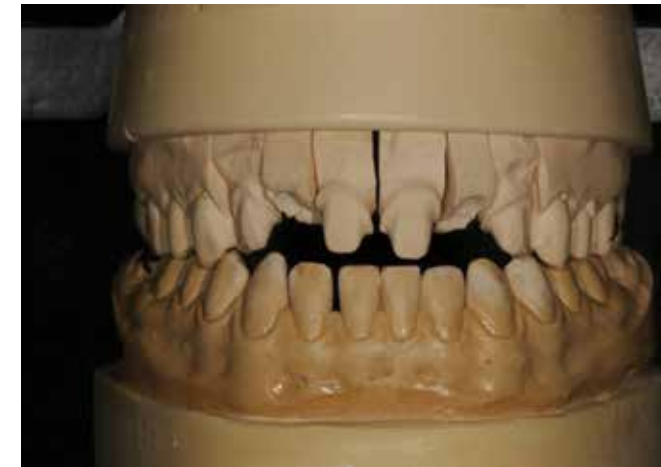

5. After contouring, but before polishing

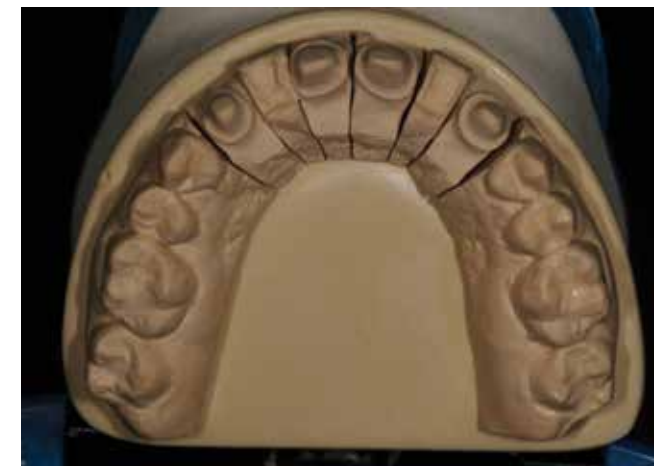## LABORATORY TECHNICIAN PHOTOGRAPHY

The following is an example of the additional photograph requirements to document the technique utilized to fabricate all cases for laboratory technicians. These photos are to be taken at 1:2 (1:3) magnification or digital equivalent. The following is a sampling of photographs used to document dental laboratory procedures. Note this is designed to show proper framing and photographic technique. Consult the Accreditation protocol for details.

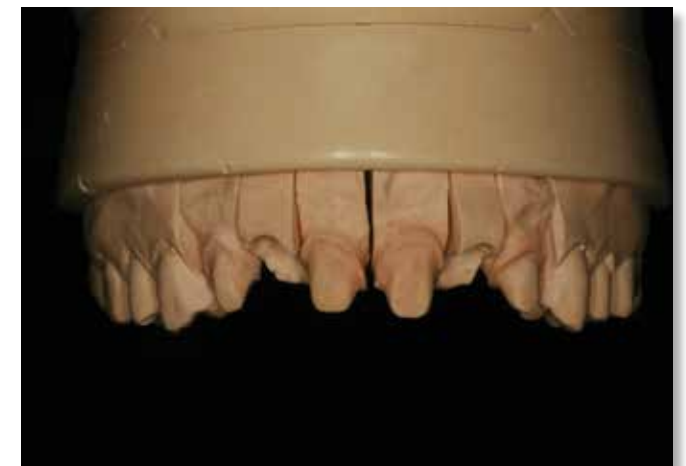These photos are to be taken at 1:2 (1:3) magnification or digital equivalent



1. Frontal view of prep model in occlusion with opposing model



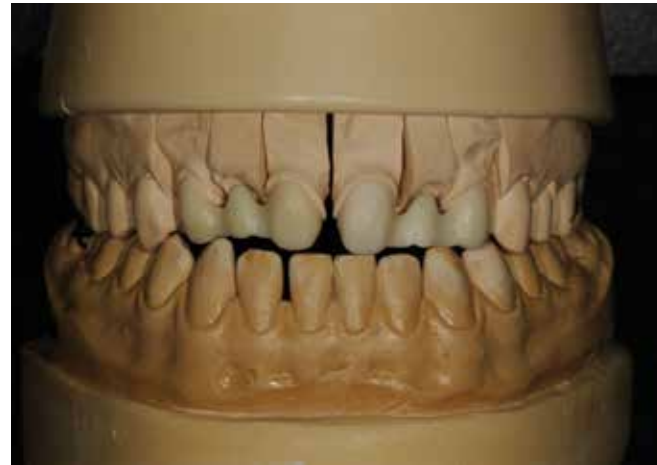2. Occlusal view of prep model



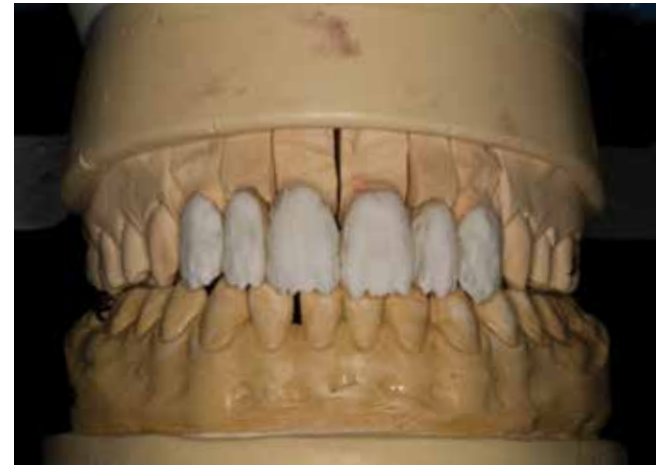3. Frontal view of lab manipulated tissue site for Case Type III

# LABORATORY TECHNICIAN PHOTOGRAPHY CONTINUED

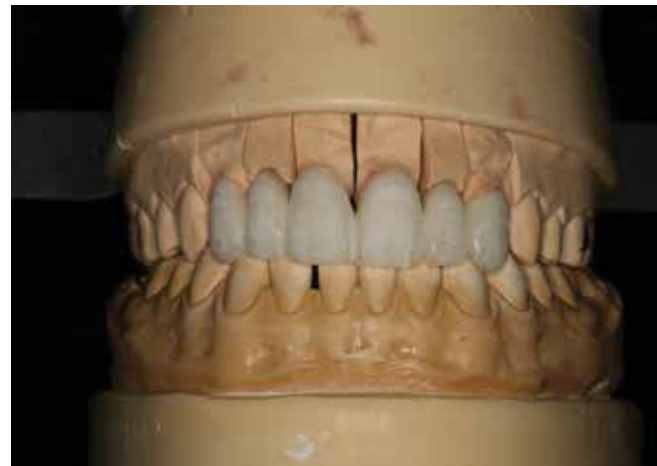These photos are to be taken at 1:2 (1:3) magnification or digital equivalent



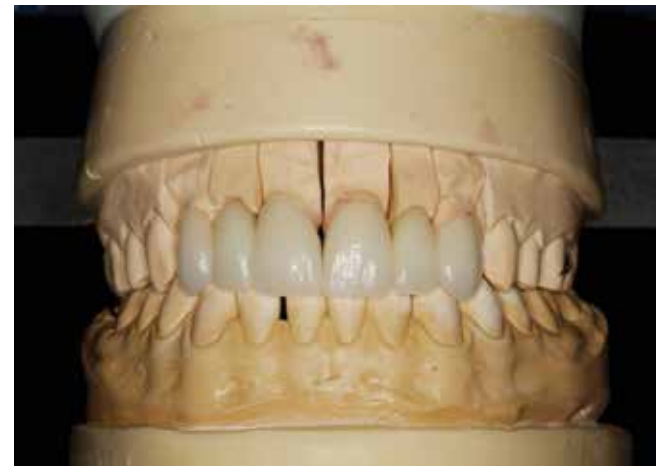4. Frontal view of bridge framework or coping design before application of veneering material



5. Frontal view of completed build-up before firing or processing

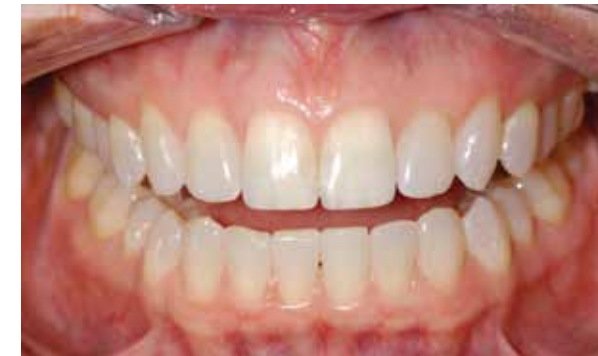

6. Frontal view of contoured bisque bake (show tissue adaptation on Case Type III)

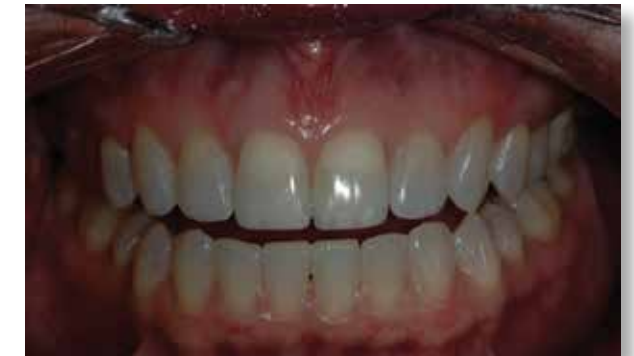

7. Frontal view of finished case on model

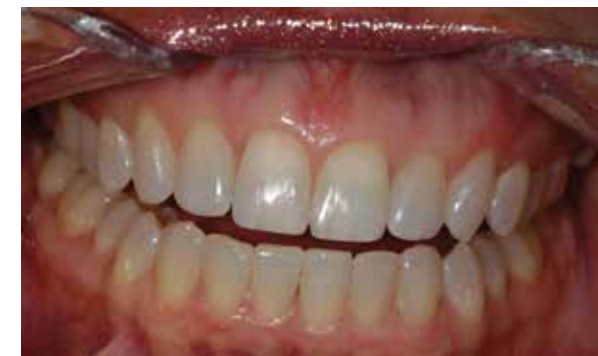# COMMON ERRORS IN DENTAL PHOTOGRAPHY



Overexposed



Underexposed



Canted

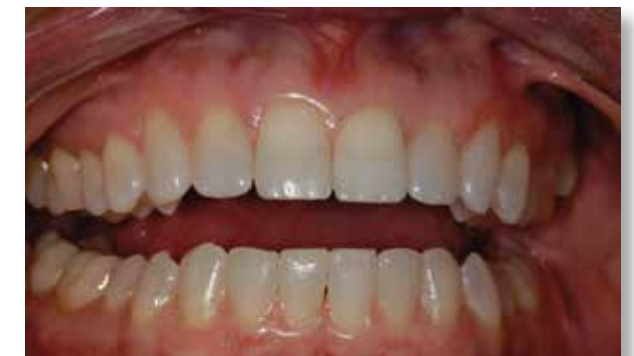

Image taken from an inferior angle and the patient's right

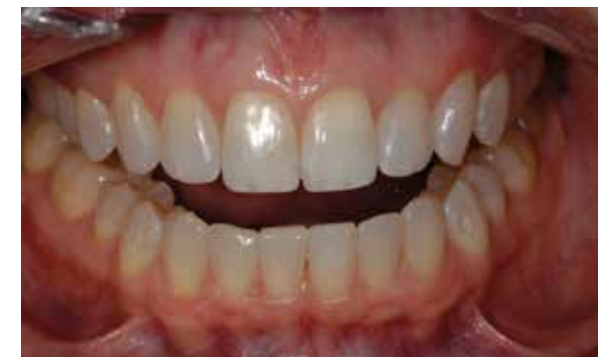
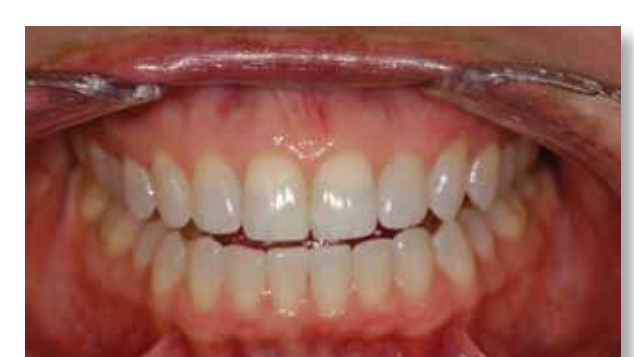
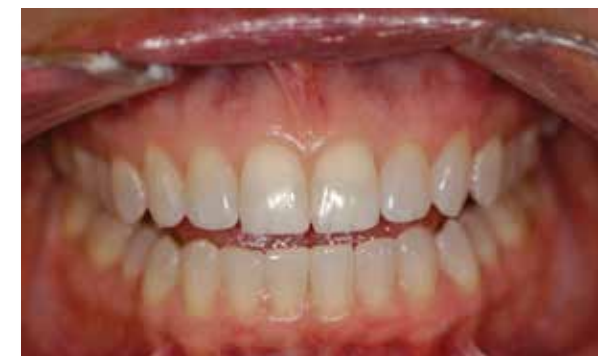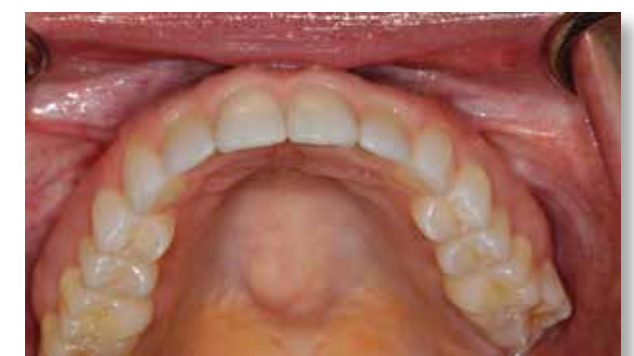Image taken from a superior angle



Lack of focus - image blurry

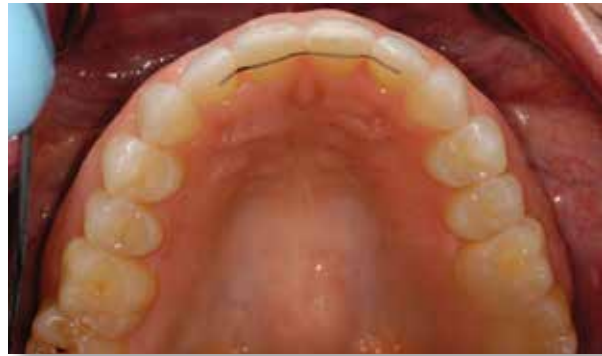

Anterior teeth are in focus but posterior teeth are out of focus. F-stop too low - improper depth of field

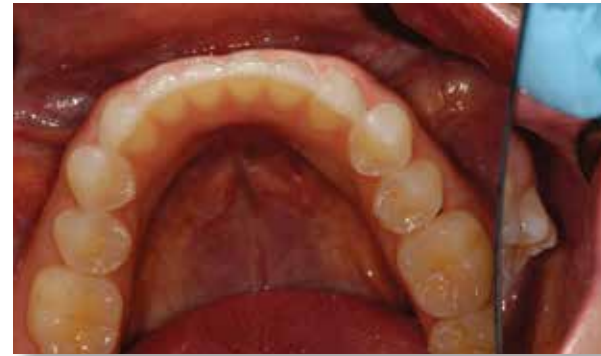

Improper angle - imaged taken from a facial perspective, without a mirror

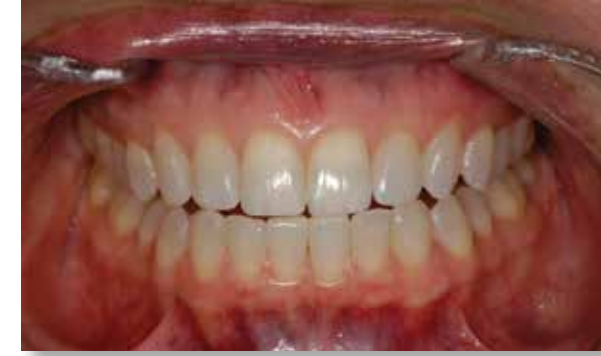# COMMON ERRORS IN DENTAL PHOTOGRAPHY CONTINUED



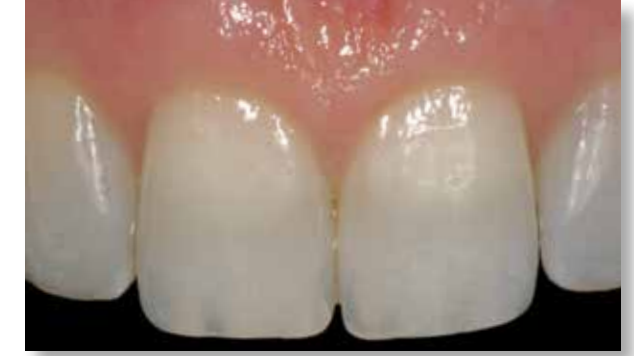*Unreflected teeth visible, fogging of mirror, debris visible in teeth*



*Improper framing – edge of mirror and unreflected teeth visible*



*Teeth inadequately separated to highlight incisal edges*



*Excessive magnification for 1:1 (1:1.5) view*



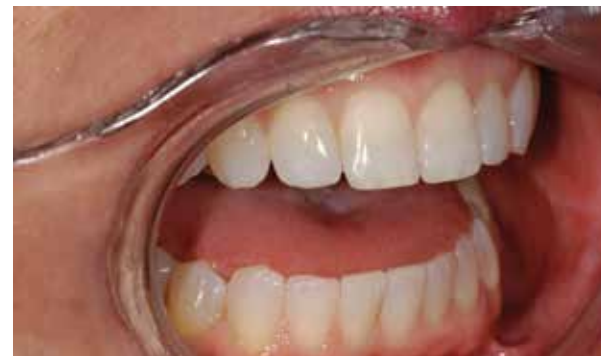*Excessive magnification for full face view*



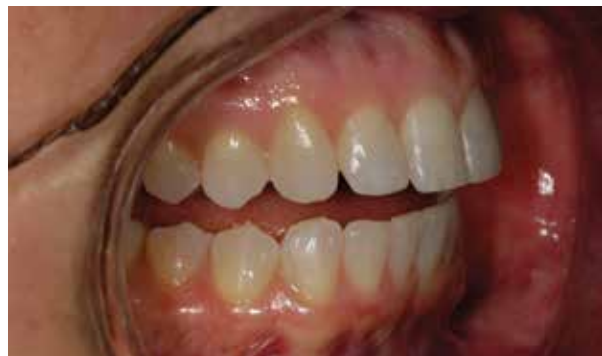*Inadequate magnification for full face view*



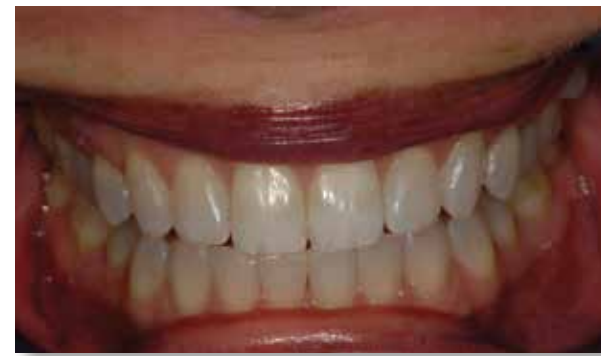*Full face image taken without a uniform backdrop*



*Improper framing and inadequate retraction*

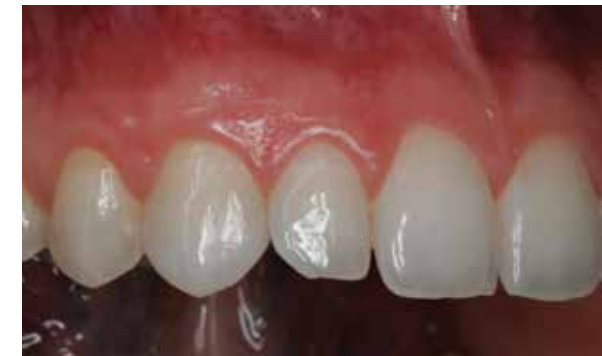

*Improper angulation – lateral view should be exposed perpendicular to the lateral incisor*

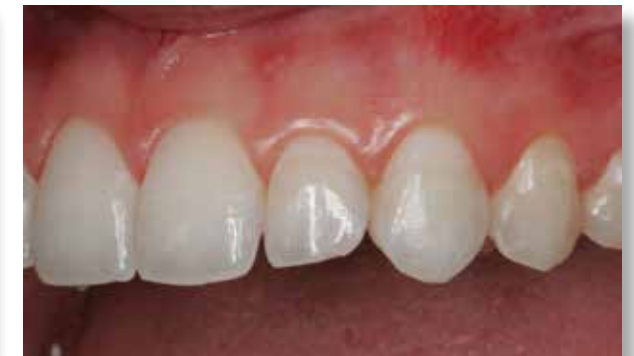

*Inadequate retraction, superior angle and maxillary and mandibular teeth inadequately separated*

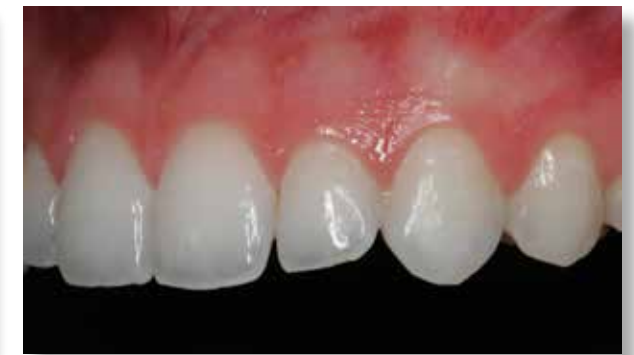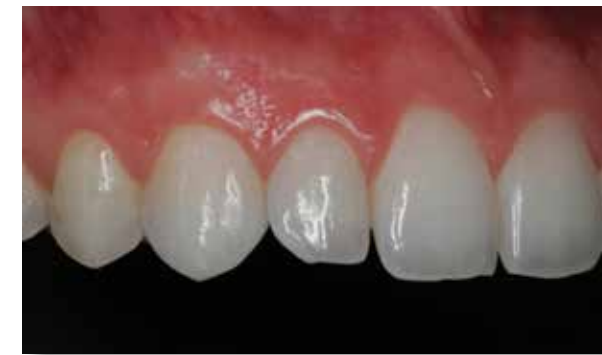## USE OF A CONTRASTING DEVICE



*Correct framing without contrasting device*



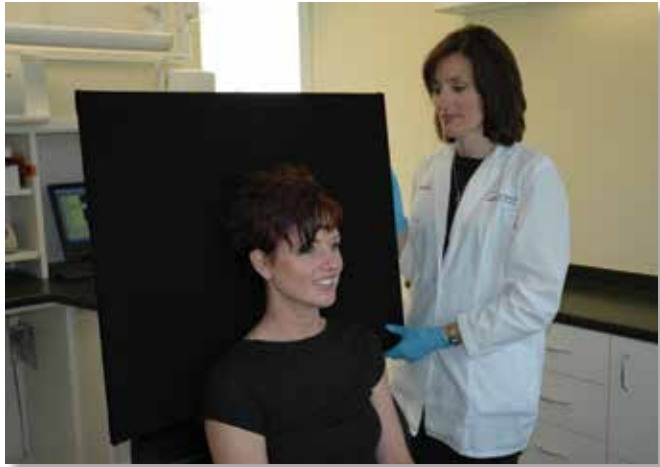
*Proper framing and placement of a contrasting device*



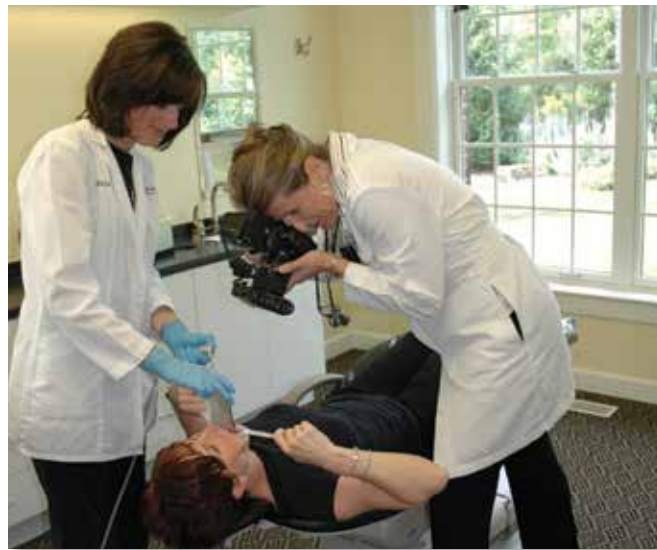*Proper Accreditation documentation requires consistency of color and exposure as shown in the required views section.*

## How To:


Capturing exceptional photography often requires an extra set of hands. An assistant can optimally position retractors, dry the teeth as needed, hold mirrors when required and prevent the mirror from fogging by using a gentle stream of air.



*Use a solid background for full face images*



*Occlusal views are aided by having patient reclined and holding retractors. An assistant holds an occlusal mirror against opposite arch and keeps mirror from fogging with a gentle stream of dry air. Photographer stands above the patient to capture the maxillary view and below the patient's head to capture the mandibular view.*



# AACD ACCREDITATION.

STEP UP. STAND OUT.

Sure, it's a journey. And yes, it's a challenge. But every single American Academy of Cosmetic Dentistry Accredited Member will tell you they became a superior dental practitioner because of it. Distinguish yourself and reach your full potential.

You'll be proud as a peacock...and have earned it.

Visit [www.AACD.com/Accreditation](http://www.AACD.com/Accreditation) to learn how to become Accredited today.